

Feb 10, 1998 V. S. 10y8m

Standard: FEM SA10

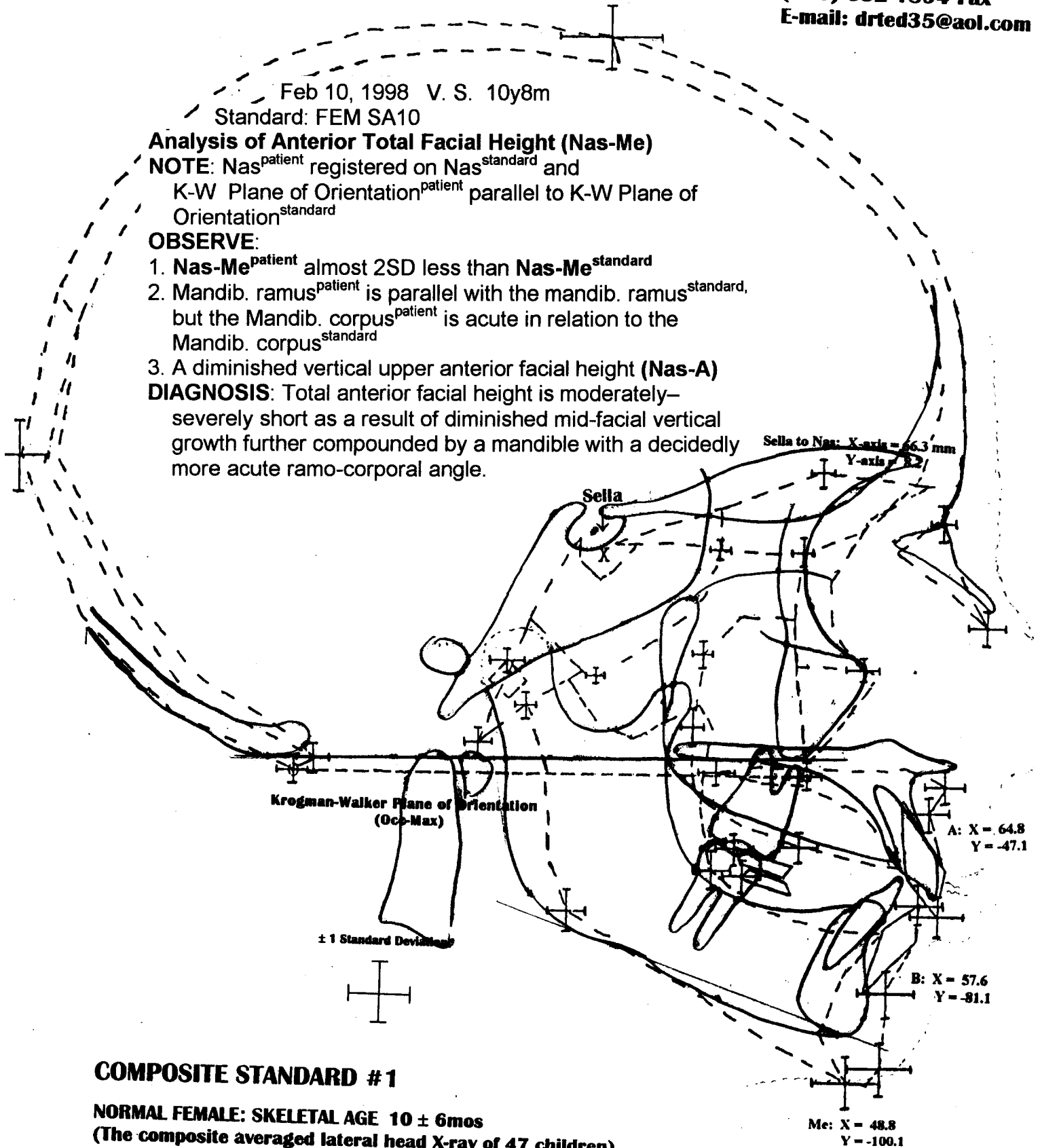
Analysis of Anterior Total Facial Height (Nas-Me)

NOTE: Nas^{patient} registered on Nas^{standard} and
 K-W Plane of Orientation^{patient} parallel to K-W Plane of
 Orientation^{standard}

OBSERVE:

1. Nas-Me^{patient} almost 2SD less than Nas-Me^{standard}
2. Mandib. ramus^{patient} is parallel with the mandib. ramus^{standard},
 but the Mandib. corpus^{patient} is acute in relation to the
 Mandib. corpus^{standard}
3. A diminished vertical upper anterior facial height (**Nas-A**)

DIAGNOSIS: Total anterior facial height is moderately-
 severely short as a result of diminished mid-facial vertical
 growth further compounded by a mandible with a decidedly
 more acute ramo-corporal angle.



COMPOSITE STANDARD #1

NORMAL FEMALE: SKELETAL AGE 10 ± 6mos
 (The composite averaged lateral head X-ray of 47 children)

W. M. Krogman Center for Research in Child Growth and Development